

## **CRANIAL CRUCIATE LIGAMENT RUPTURE**

### **ANATOMY**

There are two cruciate ligaments in the canine stifle (knee) joint, the cranial and the caudal ligaments. In human knees, they are known as the ACL and PCL. The cranial cruciate ligament is the one most commonly injured in dogs resulting in discomfort and stifle instability with subsequent arthritis. Two cartilage pads called menisci are found within each knee.

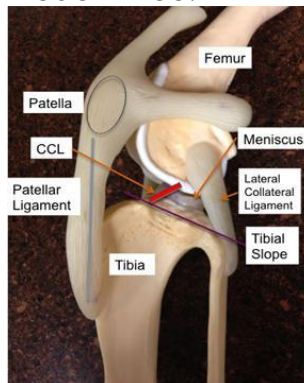
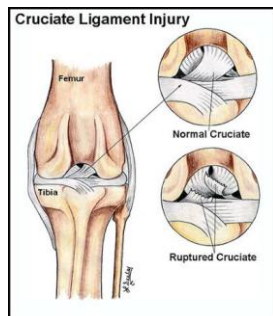


Photo credit: dfwvetsurgeons.com

### **WHY DID THE LIGAMENT RUPTURE?**

We do not fully understand the cause of cranial cruciate ligament rupture in dogs but we do know that most cases are a result of slowly progressive cranial cruciate ligament (CrCL) degeneration. A genetic cause is being researched and there is considerable support for this belief. Once weakened, the ligament can then rupture with minimal trauma.



Dogs that rupture the cruciate ligament in one stifle are at an increased risk of rupturing the ligament in the other stifle (approximately a 50% chance).



## **CLINICAL SIGNS**

Lameness is the most common symptom seen with CrCL rupture and can range from mild intermittent lameness with mild partial ligament tears to non-weight bearing lameness with complete tears and co-existent meniscal damage.

## **DIAGNOSIS**

The CrCL rupture is diagnosed by palpation (feeling the knee) and eliciting drawer motion or laxity within the joint. Dogs with mild ligament tears and those who are very tense may require sedation. Radiographs are helpful in determining the degree of arthritis, in ruling out some other orthopedic problems, and in establishing the slope of the tibial plateau.

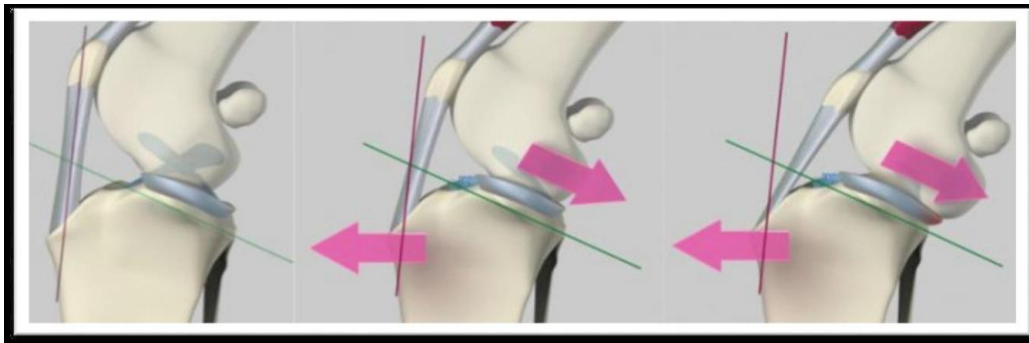


Photo credit: Fitzpatrickreferrals.co.uk

## **SURGERY**

There have been many techniques used for repair but, for the most part, only three are currently being used regularly at Steveston Veterinary Hospital.

### **Lateral Stabilizing Sutures Technique**

In small dogs, a lateral stabilizing suture technique is used whereby the suture is anchored around a small bone called the fabella at the back of the femur and passed through a drill hole in the tibia. This suture is tightened to the point of eliminating drawer motion and is left in place permanently. The remnants of the ruptured ligament are excised to theoretically lessen the progression of arthritis.

### **Tibial Plateau Leveling Osteotomy (TPLO)**

This technique is used primarily in medium and large breed dogs but can also be used in small breeds. The lateral stabilizing suture is not used in large dogs because of the high incidence of either breakage or stretching of the suture material resulting in joint laxity, lameness, and the progression of arthritis.



---

The TPLO technique changes the slope of the tibial plateau to a near level slope which eliminates the need for the cruciate ligament in preventing tibial thrust. The top of the tibia is cut with a special bone saw below the joint surface and rotated to a near level position. It is then held in place with a special bone plate and screws while the bone heals. This hardware is normally left in place permanently.

### **Cora Based Leveling Osteotomy (CBLO)**

This is also a leveling type of surgery which has advantages in certain situations such as immature large breed dogs.

In the above types of surgery, torn menisci are excised and are eventually partially replaced to some degree with regrowth of mensci consisting of fibrocartilage. Torn menisci are responsible for much of the discomfort experienced by these dogs.

### **Tibial Tubercle Advancement (TTA)**

Another technique for cruciate repair is called the TTA which stands for tibial tubercle advancement. With this approach, the tibial crest is cut and moved forward and held in position with a spacer and a special plate with screws while the gap created fills in with new bone. This technique is not currently used at Steveston Veterinary Hospital for many reasons. The procedure is an invasive one with complication rates reported to be higher than those for the TPLO. It is not appropriate for dogs with a slope greater than 28 degrees. The incidence of post operative meniscal tears is statistically higher. Finally, clients are generally very happy with the outcome of the TPLO procedure.

## **RECOVERY**

Patients are rechecked 10-14 days postoperatively at the time of staple or suture removal. Most are bearing some weight on the leg at that time but full recovery generally takes 8-12 weeks. Activity must be markedly restricted at all times, particularly for the first 6 weeks. There is potential for serious problems and reduced surgical success if activity is not restricted postoperatively.

## **COMPLICATIONS**

Complications are infrequent. Swelling in the area of the hock (ankle) is common after CBLO and TPLO surgery and usually resolves within a few days. Licking the incision is a concern and when this occurs, an E-collar is used until the sutures are removed. Other potential but fortunately uncommon complications include breakage of the implants, infection, fracture of the tibial tuberosity, inflammation of the patellar tendon, and delayed healing. Many complications can be avoided with proper surgical technique.



## **PROGNOSIS**

Large breed dogs treated with TPLO and CBLO are more comfortable postoperatively, recover more quickly, and appear to have decreased development of arthritis than dogs treated with other methods. The client and surgeon satisfaction rates are very high. Dogs that have had a considerable delay in receiving surgery generally have more advanced arthritis. Depending on the severity of the arthritis at the time of surgery, dogs may show signs of mild lameness to a more persistent lameness in cases with severe osteoarthritis. Anti-inflammatory medication may be required. The majority of dogs treated with surgery do extremely well.